

# EVALUATION OF ANTEMORTEM SAMPLING TO ESTIMATE CHRONIC WASTING DISEASE PREVALENCE IN FREE-RANGING MULE DEER

LISA L. WOLFE, Colorado Division of Wildlife, Wildlife Research Center, 317 West Prospect Road, Fort Collins, CO 80526, USA, and Natural Resource Ecology Laboratory, Colorado State University, Fort Collins, CO 80523, USA

MARY M. CONNER, Colorado Division of Wildlife, Wildlife Research Center, 317 West Prospect Road, Fort Collins, CO 80526, USA, and Department of Fishery and Wildlife Biology, Colorado State University, Fort Collins, CO 80523, USA

THOMAS H. BAKER, Colorado Division of Wildlife, Wildlife Research Center, 317 West Prospect Road, Fort Collins, CO 80526, USA, and Natural Resource Ecology Laboratory, Colorado State University, Fort Collins, CO 80523, USA

VICTORIA J. DREITZ, Natural Resource Ecology Laboratory, Colorado State University, Fort Collins, CO 80523, USA

KENNETH P. BURNHAM, Colorado Cooperative Fish and Wildlife Research Unit, Colorado State University, Fort Collins, CO 80523, USA

ELIZABETH S. WILLIAMS, Wyoming State Veterinary Laboratory, Department of Veterinary Sciences, University of Wyoming, 1174 Snowy Range Road, Laramie, WY 82070, USA

N. THOMPSON HOBBS, Natural Resource Ecology Laboratory, Colorado State University, Fort Collins, CO 80523, USA

MICHAEL W. MILLER,<sup>1</sup> Colorado Division of Wildlife, Wildlife Research Center, 317 West Prospect Road, Fort Collins, CO 80526, USA

**Abstract:** We conducted a field study to evaluate tonsillar biopsy immunohistochemistry (IHC) as a tool for diagnosing chronic wasting disease (CWD) in live, free-ranging mule deer (*Odocoileus hemionus*) and estimating CWD prevalence. Initially, we evaluated and refined techniques for collecting tonsillar biopsies from mule deer. Using a simple mouth gag and a 6-mm biopsy forceps, and taking the biopsy starting at the rostral rim of the tonsillar sinus, we obtained 155/161 (96%) samples that yielded  $\geq 1$  lymphoid follicle. To compare antemortem and postmortem survey techniques and assure biopsy-based estimates would not substantially underestimate “true” prevalence, we examined tonsillar biopsies from 161 free-ranging mule deer from 2 populations where CWD is endemic. We then calculated prevalence ( $p_b$ ) and compared this to prevalence ( $p_h$ ) estimated from tonsil samples from 161 deer harvested or culled in spatial and temporal proximity to our study areas; we considered the latter a close approximation of “true” prevalence. Biopsy-based prevalence estimates exceeded prevalence estimated by tonsillar IHC of samples from harvested or culled deer. Although 95% CIs for  $p_h - p_b$  included 0 for area-specific estimates, biopsy-based estimates were  $\geq 3$  times higher than harvest-based estimates in both study areas. Moreover, when data from both study areas were combined,  $p_h$  ( $= 0.025$ ) was lower than  $p_b$  ( $= 0.081$ ) and the 95% CI for  $p_h - p_b$  ( $-0.104$  to  $-0.007$ ) did not include 0. Observed differences in prevalence most likely reflected spatial or temporal variation in populations (or subpopulations) of deer sampled. Tonsillar biopsy IHC appears to be reliable for detecting CWD infections in live mule deer and estimating prevalence in affected populations, thereby representing a new tool with potential utility in CWD management, particularly in areas where harvest-based sampling is infeasible.

**JOURNAL OF WILDLIFE MANAGEMENT 66(3):564–573**

**Key words:** chronic wasting disease, Colorado, diagnosis, immunohistochemistry, mule deer, *Odocoileus hemionus*, prion, transmissible spongiform encephalopathy.

Chronic wasting disease (Williams and Young 1980, 1982) is an endemic prion disease of free-ranging deer (*Odocoileus* spp.) and elk (*Cervus elaphus nelsoni*) populations in northeastern Colorado and southeastern Wyoming, USA (Miller et al. 2000). In deer, and perhaps in elk, unmanaged CWD epidemics appear to pose a substantial threat to long-term viability of infected populations (Gross and Miller 2001). Consequently, preventing the spread and reducing the occurrence of CWD in endemic areas have become the primary goals for managing infected deer and elk populations in northeastern Colorado (Colorado Division of Wildlife 2001).

Successful management of CWD appears dependent on early detection and elimination of infected individuals and endemic foci (Gross and Miller 2001). Unfortunately, strategies for detecting and managing foci of CWD presently are hampered by the lack of reliable methods for diagnosing infection in live deer and elk. Reliance on postmortem samples from harvested or culled animals limits opportunities for identifying infected subpopulations, particularly in suburban and rural residential areas of northeastern Colorado where few deer may be harvested annually and public support for culling ostensibly healthy animals is at best tenuous. As a result, both new and existing CWD foci may persist undetected in such areas and serve as reservoirs for the maintenance and geographic spread of CWD in the wild (Gross and Miller 2001).

<sup>1</sup> E-mail: mike.miller@state.co.us

Management of scrapie, a relatively common prion disease of domestic sheep, also has suffered historically from unavailability of an antemortem (live-animal) test. Recently, however, observations that lymphoid accumulation of disease-associated prion protein (PrP<sup>res</sup>) precedes development of detectable neurological lesions and clinical signs led to development of immunohistochemistry (IHC) for use in preclinical and clinical diagnosis of scrapie in sheep (Miller et al. 1993; Schreuder et al. 1996, 1998; van Keulen et al. 1996; O'Rourke et al. 1998a,b, 2000; Andréoletti et al. 2000). Positive staining of lymphoid tissues (particularly retropharyngeal lymph nodes, tonsils, and mesenteric lymph nodes) also has been observed in mule deer exposed to CWD (Sigurdson et al. 1999; Miller et al. 2000; Miller and Williams 2002), and appears to be an early indicator of preclinical disease in this species as well. Tonsillar IHC using monoclonal antibody (MAb) F99/97.6.1 (O'Rourke et al. 2000, Spraker et al. 2002) is both sensitive and specific in detecting CWD-infected mule deer in harvest-based epidemiological surveys (Miller and Williams 2002): false-positive results have not been observed using tonsillar IHC, and false-negative results are rare.

Antemortem scrapie tests are based on biopsy and examination of lymphoid tissues, typically from tonsil or nictitating membrane (O'Rourke et al. 1998b, 2000; Schreuder et al. 1998). Similarly, preliminary data from captive and free-ranging mule deer indicate that tonsillar biopsy has potential application in antemortem diagnosis of CWD (Colorado Division of Wildlife, unpublished data). Here, we evaluated the utility of antemortem sampling to estimate CWD prevalence in free-ranging mule deer populations. The specific objectives of our study were to evaluate tonsillar biopsy as a tool for antemortem diagnosis of CWD in free-ranging mule deer and to compare estimated CWD prevalence based on tonsillar biopsy data to prevalence estimated from harvest-based survey data for deer from the same populations.

## STUDY AREA

Our study focused on sampling 2 native mule deer populations residing in portions of north-central Colorado where CWD was endemic (Miller et al. 2000). One population resided primarily in Estes Park (EP) and the other near the mountain residential area of Glacier View Meadows (GVM; Fig. 1). Deer habitat in the 1,662 km<sup>2</sup>-EP study area included coniferous mountain shrub types intermixed with agricultural, recreational, and subur-

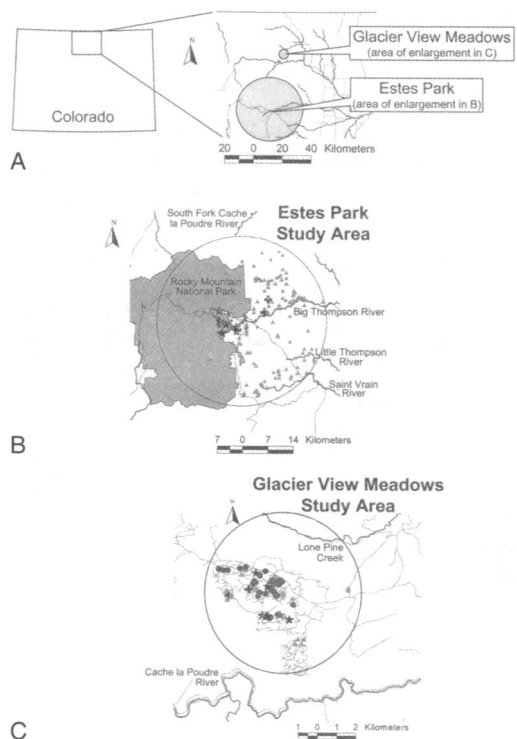


Fig. 1. Study areas in north-central Colorado, USA, where tonsillar biopsy immunohistochemistry was evaluated for diagnosing chronic wasting disease in free-ranging mule deer. (A) One population resided primarily in Estes Park (EP) and the other in the mountain residential area of Glacier View Meadows (GVM). (B) Deer captured and biopsied in the 1,662-km<sup>2</sup> EP study area came primarily from residential areas and national park lands, whereas deer harvested in this area came primarily from national forest and private lands east of the town of Estes Park. (C) Deer captured and biopsied in the 50-km<sup>2</sup> GVM study area came from approximately the same residential areas where deer had been culled previously. Circles represent biopsy-negative deer, stars represent biopsy-positive deer, triangles represent negative harvested (EP) or culled (GVM) deer, and crosses represent positive harvested or culled deer; lines represent rivers and roadways.

ban developments at lower elevations; deer habitat in the 50 km<sup>2</sup>-GVM study area primarily was coniferous mountain shrub type intermixed with suburban developments throughout. These 2 areas represent geographically separate deer populations from 2 different river drainages (Fig. 1A). Some individual deer in each of these populations were sedentary, and others moved seasonally to higher elevation alpine summer ranges (M. M. Conner and M. W. Miller, unpublished data). We captured and sampled most deer during April–June and August–October 2001 while they were on winter and transitional ranges.

## METHODS

### Tonsillar Biopsy Sampling Technique

Initially, variations on techniques described elsewhere (Schreuder et al. 1998; Colorado Division of Wildlife, unpublished data) were systematically evaluated to develop a repeatable sampling method. We sampled 58 free-ranging mule deer in these preliminary evaluations in conjunction with ongoing field studies of deer movement patterns (M. M. Conner and M. W. Miller, unpublished data). All deer were anesthetized with various combinations of thiafentanil, carfentanil, ketamine, tiletamine and zolazepam, medetomidine, and xylazine prior to biopsy sampling (L. L. Wolfe and M. W. Miller, unpublished data). Deer were captured either by darting or Clover trapping (Clover 1956); those deer not already anesthetized during capture were anesthetized before tissue samples were collected. In addition, we sampled 17 deer captured and euthanized in conjunction with CWD management programs to allow multiple sample collections from a single animal. Biopsies were performed by a veterinarian (L. L. Wolfe and/or M. W. Miller) with previous experience in these procedures. Minor bleeding, when it occurred, was controlled with a gauze pad and mild pressure on the biopsy site. All live deer sampled were marked with individually identifiable metal ear tags and either flexible neck bands, plastic ear tags or, in some cases, radiocollars and given penicillin G benzathine and procaine ( $1.8 \times 10^6$  units, injected subcutaneously) prior to recovery and release. Biopsy instruments were disinfected between uses by soaking for  $\geq 1$  hr in a phenolic solution (LpH<sup>®</sup>ag; Steris, St. Louis, Missouri, USA) followed by autoclaving at 134 °C and about 2 atmospheres pressure.

Technique variables included methods for visualizing the tonsillar sinus, biopsy instrument, and specific tissue sampling approach. We evaluated 3 visualization techniques (manually holding the mouth open, using a simple mouth gag, or inserting a swine vaginal scope attached to a flashlight); in all cases, supplemental lighting was provided via a head lamp worn by the operator and/or a small hand-held flashlight. Tissue biopsies were collected using a 30-cm Jackson rectal biopsy forceps (Sontec Instruments, Englewood, Colorado, USA); 2 cup sizes (4 and 6 mm) were evaluated. Three sampling approaches also were compared: biopsies were taken by inserting the biopsy forceps directly into the tonsillar sinus, rostral to the sinus, or by taking the first bite at the rostral rim of the sinus. At

least 4 tissue bites were taken with each technique for evaluation. We abandoned specific technique combinations as soon as it became apparent that they failed to consistently yield usable samples.

Extracted tonsillar tissue was preserved in 10% neutral buffered formalin for histological evaluation. Tonsillar biopsies were examined via histopathology and IHC using MAb F99/97.6.1 (VMRD, Pullman, Washington, USA); IHC techniques were as described previously (Miller and Williams 2002). Biopsies initially were evaluated microscopically for presence of lymphoid follicles and the number of follicles recorded. Biopsies containing at least 1 lymphoid follicle were regarded as usable; these were further evaluated for the presence of IHC staining in follicles and categorized as CWD-positive or -negative based on staining. We used Fisher's exact tests to compare proportions of usable samples obtained under different sampling strategies, and used  $\alpha = 0.05$  in assessing significant differences between strategy-specific proportions of usable samples.

### Sample Quality and Correction for Potential False Negatives from Biopsy Samples

Based on preliminary field data, we anticipated that even with optimal sampling technique some proportion ( $\leq 10\%$ ) of the biopsies might be inadequate for evaluation because no lymphoid follicles were discernable. However, to minimize the number of otherwise wasted captures, we wanted to assure that all samples containing at least 1 follicle could be used in estimating prevalence. Because a single positive follicle could be considered sufficient to classify a sampled deer as CWD-positive, we also wanted to use samples with a single negative follicle in estimating prevalence.

Although false-positives were unlikely (Miller and Williams 2002), we recognized that false-negative biopsy samples could occur when few follicles were available for examination. If false-negative samples were common among biopsy samples, then prevalence estimates based on biopsy likely would underestimate prevalence when compared to estimates derived from examining entire cross-sections of tonsils collected from harvested deer. Consequently, we wanted a means of using the number of follicles present in negative samples to correct the probability of a negative classification based on examination of few versus many follicles. To make this correction, we derived a correction factor for sample quality based on the probability a deer was actually CWD-positive given that  $n$  negative follicles were

present in the tonsil biopsy (see Appendix 1).

We used IHC slides from 64 harvested deer previously identified as CWD-positive (Miller and Williams 2002) to count the number of positive and negative follicles in a representative cross-section of tonsillar tissue. Only intact follicles were counted. From these count data, we constructed a frequency distribution for the relative proportions of positive follicles encountered in CWD-infected deer. We then used these data and local CWD prevalence estimates to calculate the correction factor for negative biopsies based on the number of follicles discernable in each biopsy sample collected (see Appendix 1 for detailed mathematical explanation).

### Comparison of Prevalence Estimates

We compared CWD prevalence estimated from tonsillar biopsies ( $p_b$ ) to prevalence estimated from existing harvest-based survey data ( $p_h$ ; also estimated via tonsillar IHC on tissues collected postmortem). Our study was designed to determine whether prevalence estimates derived from these 2 techniques were comparable. Thus, our null and alternative hypotheses were reversed from their typical order: our alternative hypothesis was that there was no difference between the methods. Based on preliminary data and our experience with CWD diagnostic techniques (Miller and Williams 2002; Spraker et al. 2002), it seemed unlikely that biopsy-based estimates would overestimate prevalence as compared to harvest-based estimates. Assuming that the latter prevalence estimate averaged about 0.1 for our study areas (Miller et al. 2000; M. W. Miller, unpublished data), and given the variation in prevalence observed annually, we regarded  $\leq 50\%$  differences in estimates between tests as a reasonable benchmark for comparing techniques.

Because we were not interested in detecting a small difference between the methods, but rather in ensuring that these 2 methods were comparable, we did not use traditional power calculations to determine the sample size. Instead, we used a more intuitive approach examining the 95% confidence interval (CI) of the difference between prevalence estimates (K. P. Burnham, unpublished data). We assumed that the sampling distribution of the estimated difference in prevalence,  $\hat{p}_h - \hat{p}_b = \hat{d}$ , was normal with some mean,  $p_h - p_b = d$ , and theoretical variance

$$\frac{p_h(1-p_h)}{n} + \frac{p_b(1-p_b)}{n}.$$

For simplicity, we also assumed equal  $n$  for each method. We wanted the lower end of the 95% CI to be slightly greater than zero if a difference in estimates existed; we regarded 0.001 as the critical limit for this difference. Consequently,  $n$  was calculated based on the lower 95% CI; because only underestimation of prevalence was of concern, we used  $Z_a (= 1.645)$  rather than  $Z_{a/2}$ . It followed that

$$0.001 = (p_h - p_b) - 1.645 \sqrt{\frac{p_h(1-p_h)}{n} + \frac{p_b(1-p_b)}{n}},$$

where  $p_b$  was the prevalence estimated from biopsy samples and  $p_h$  was the prevalence estimated from harvest-derived samples; both  $p_b$  and  $p_h$  were unknown parameters that would be estimated from the data. Based on preliminary data from our study areas, we estimated  $p_h = 0.1$ ; assuming a 50% lower estimate for  $p_b$ ,  $p_b = 0.05$ . It followed that solving for  $n$ ,  $n = 155$ . Thus, we estimated that comparisons based on usable biopsies from a random sample of  $\geq 155$  captured deer and a geographically corresponding sample of  $\geq 155$  harvested deer would be sufficient to allow us to decide whether tonsillar biopsy-based prevalence estimates could be regarded as equivalent to harvest-based estimates in future studies.

For comparisons of prevalence estimates, we captured, sampled, and handled free-ranging mule deer from the EP and GVM populations as described above; samples were stored, processed, and evaluated as described above. The number of follicles in each sample, and the number staining positive, were recorded for each sample. We estimated CWD prevalence as the ratio of positive to total samples. For harvest-based estimates of prevalence, we used data from mule deer harvested (EP) or culled (GVM) in spatial and temporal proximity to sites of biopsy sampling (M. W. Miller, unpublished data). For the EP area, we estimated prevalence via harvest samples collected during 1999 and 2000 fall hunting seasons that were within 23 km of the center of Estes Park (Fig. 1B); we used combined October–December 1999 and October–December 2000 harvest data because October–December 2000 data alone yielded an inadequate sample size. This 23-km radius area encompassed similar habitats for both sampling methods and was the minimum area sufficient to provide an adequate number of harvest samples. For the GVM area, we estimated prevalence from a sample of apparently healthy deer randomly culled during April 2001. We used

this sample because, by design, it was collected close in space (Fig. 1C) and time to tonsillar sampling. We regarded the culling sample as similar to a harvest sample in that deer were opportunistically taken from the GVM area.

Only adult ( $\geq 1$  yr old) deer were used to estimate prevalence for all samples, and only deer with  $\geq 1$  discernable lymphoid follicle were used to estimate prevalence via biopsy sampling. We calculated the difference and standard error of the difference in prevalence estimates between harvest and tonsil samples ( $p_h - p_b$ ) as described for estimating sample sizes needed for comparisons. As above, we used 0.001 as the critical limit for demonstrating a difference between sampling techniques: if the lower bound of the 95% CI on the difference in prevalence estimates was  $<0.001$ , then biopsy-based estimates did not underestimate "true" prevalence as estimated by examining samples from harvested and culled deer.

## RESULTS

### Tonsillar Biopsy Sampling Technique

The quality of biopsy samples was dramatically affected by sampling technique ( $P = 0.000007$ ). Biopsy cup size (4 mm vs. 6 mm) appeared to have the greatest influence on number of follicles recovered—using a biopsy forceps with a 6-mm cup consistently yielded more samples with follicles (38/50) than a 4-mm cup (8/25) across various visualization and site combinations. We attributed this difference to the ability to collect larger tissue pieces with the 6-mm cup. Manually holding the mouth open proved dangerous to the operator and instruments and was discontinued. Using the swine vaginal scope was easy, provided good visualization of the tonsillar sinus, and protected the biopsy instruments; however, usable sample yield (10/30) was much lower than when using the mouth gag (36/45). In retrospect, it appeared that the scope may have somehow distorted tonsillar tissue when pressed against the soft palate, thereby diminishing sample quality.

The most consistent biopsy approach was taking the first bite at the rostral rim of the tonsillar sinus, then rotating the biopsy forceps to take subsequent bites that included the sinus; using this approach, 23/24 samples had follicles (vs. 12/17 when sampling directly from the sinus; other variables held constant). Inserting the forceps directly into the sinus or attempting to take deep bites seemed to bypass follicular tissue alto-

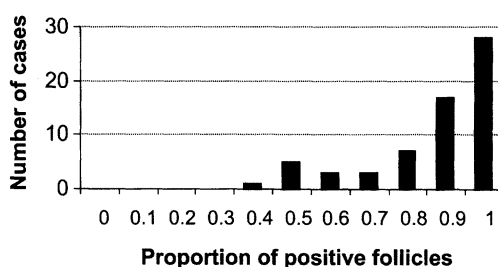


Fig. 2. Frequency distribution of lymphoid follicle involvement (positive/total) in cross-sections of tonsils from 64 mule deer infected with chronic wasting disease (CWD), as determined by immunohistochemistry (IHC). Data from this distribution were used in deriving an equation to correct the probabilities of IHC-negative biopsies based on the number of discernable follicles as a means of correcting biopsy-based CWD prevalence estimates.

gether in many cases. Overall, by using a simple mouth gag and a 6-mm biopsy forceps, and by taking the biopsy starting at the rostral rim of the tonsillar sinus, we collected 155/161 (96%) samples that yielded 1 lymphoid follicle.

### Sample Quality and Correction for Potential False Negatives from Biopsy Samples

We used CWD-positive deer from the harvest sample to estimate the distribution of the proportion of positive follicles for the correction factor. Sections of tonsillar tissue from 64 CWD-positive deer included 8 to 196 identifiable follicles. Follicle counts represented the minimum number of follicles actually included in a sample. In most samples, additional follicles were present but were distorted in sampling; regardless of staining, these were not counted in estimating follicle numbers or proportion of follicles involved in positive cases. Among these cases, the proportion of follicles staining positive in cross-sections of tonsil ranged from 30.4% (17/56) to 100% (143/143); in 43.8% (28/64) of the deer examined,  $>90\%$  of the discernible follicles stained positive (Fig. 2). On average, 83% of follicles stained positive in CWD-positive deer examined.

We collected 161 usable biopsy samples that included at least 1 identifiable follicle from the 2 study areas (Table 1); of these, 79 (49%) had 10 follicles. Thirteen of 161 usable biopsy samples showed positive staining in lymphoid follicles, indicating CWD infection. Biopsies with as few as 3 follicles yielded positive tests. The proportion of positive-staining follicles in biopsy samples ranged from 40% to 100%.

Table 1. Comparison of chronic wasting disease prevalence estimates based on tonsil biopsy samples from live mule deer ( $p_b$ ) or on postmortem samples from harvested or culled mule deer ( $p_h$ ) in north-central Colorado, USA.

Source	Biopsy-based data and estimates			Harvest-based data and estimates			Difference	
	Positive/ total	Prevalence ( $p_b$ )	95% CI <sup>a</sup>	Positive/ total	Prevalence ( $p_h$ )	95% CI <sup>a</sup>	$p_h - p_b$	95% CI
Estes Park	6/117	0.051	0.022–0.103	2/117	0.017	0.004–0.054	–0.034	–0.081 to 0.012
Glacier View Meadows	7/44	0.159	0.074–0.287	2/44	0.046	0.010–0.138	–0.114	–0.238 to 0.011
Total	13/161	0.081	0.046–0.130	4/161	0.025	0.008–0.058	–0.056	–0.104 to –0.007

<sup>a</sup> 95% CI are an equal-tailed Jeffreys prior interval for binomial data (Brown et al. 2001).

Comparison of Prevalence Estimates

Tonsillar biopsy-based CWD prevalence estimates approximated prevalence estimates based on IHC of tonsillar tissues from harvested mule deer (Table 1). Contrary to our initial concerns about underestimation using biopsy data, CWD prevalence estimated via tonsillar biopsy IHC actually exceeded prevalence estimated by sampling harvested or culled deer (Table 1). Although 95% CI for  $p_h - p_b$  included 0 for area-specific estimates, biopsy-based estimates were 3 times higher than harvest-based estimates in both study areas (Table 1). Moreover, when data from both study areas were combined,  $p_h$  (= 0.025) was lower than  $p_b$  (= 0.081), and the 95% CI for  $p_h - p_b$  (–0.104 to –0.007) did not include 0.

Adjusting biopsy-based estimates to account for sample quality only exaggerated these differences. Biopsy-based prevalence estimates increased slightly (<1.1%) when we corrected for false negatives: when assumed values of ( $\pi$ ) (approximate “true” CWD prevalence in the sampled population at time  $t$  if every tonsil follicle was examined for all deer in the population; see Appendix 1) were based on harvest data, the estimated prevalence increased from 0.0508 to 0.0514 in EP and from 0.1591 to 0.1596 in GVM; when assumed values of ( $\pi$ ) were based on biopsy data themselves, the estimated prevalence increased from 0.0508 to 0.0526 in EP and from 0.1591 to 0.1610 in GVM.

DISCUSSION

Tonsillar biopsy IHC appears to be a reliable method of detecting CWD infections in live mule deer and estimating prevalence in affected populations. Overall, biopsy-based CWD prevalence estimates exceeded estimates based on sampling of deer harvested or culled in the same vicinity. We regarded this as a real difference because tonsillar IHC served as the basis for both biopsy- and

harvest-based prevalence estimates. Moreover, because tonsillar IHC using MAb F99/97.6.1 is highly specific for CWD infection in mule deer (Miller and Williams 2002; Spraker et al. 2002), it is highly unlikely that any of these were false-positive tests. Because PrP<sup>res</sup> accumulation in tonsil cannot be detected in mule deer early in the course of CWD infection (Sigurdson et al. 1999; E. S. Williams and M. W. Miller, unpublished data), both harvest- and biopsy-based estimates of CWD prevalence still represent slight underestimates of true prevalence. However, data from tonsillar biopsy IHC should be regarded as equivalent to data from tonsillar IHC in harvested or culled deer in estimating CWD prevalence and assessing spatial and temporal epidemic trends.

Our observations of consistently higher prevalence among biopsied deer (Table 1) may offer insights into spatial or temporal dynamics of CWD. Differences in prevalence could be a simple artifact of sampling or spatial variation. For example, 5 of the 7 biopsy-positive deer at GVM came from a relatively small area that was not sampled as heavily during culling (Fig. 1C); similarly, deer biopsied in EP were from residential areas and national park lands where harvest does not occur (Fig. 1B). Temporal variation also may underlie these differences: GVM deer were culled in late winter (Apr) but biopsied in summer and early fall (Aug–early Oct), so observed differences in prevalence could reflect seasonal variation (Conner et al. 2000). Alternatively, these differences could be evidence of greater risk or exposure to the CWD agent among some subpopulations of deer. In the GVM area, about half of the mule deer are seasonally migratory and the others are year-round residents (M. M. Conner and M. W. Miller, unpublished data). Culling occurred in late winter before the migratory subpopulation had begun to move; in contrast, biopsies were collected in summer and early

fall from deer that were more likely to be year-round residents. Higher prevalence in these resident deer may reflect increased dose and/or frequency of exposure to the CWD agent, either as a result of simply having smaller home ranges or as a result of some natural or artificial feature of these home ranges. Because this area is largely residential, the presence of artificial (and illegal) feeding and water sources may be influencing CWD prevalence in the GVM area. Similarly, some biopsied subpopulations of EP deer winter in residential areas (M. M. Conner and M. W. Miller, unpublished data) where artificial feeding and water sources, or some other factor, may increase exposure or otherwise facilitate CWD transmission. Understanding these apparent differences in CWD prevalence on a local level could enhance the efficacy of CWD management efforts, and consequently deserves further study.

Using a simple mouth gag to take biopsies starting at the rostral rim of the tonsillar sinus with a 6-mm biopsy cup, >95% of our biopsy samples contained at least 1 discernible lymphoid follicle. These counts included only intact follicles and thereby represented a minimum number of follicles actually included in the sample. Additional follicles were undoubtedly collected in most samples, but were distorted in sampling. Although damaged follicles were not counted here, the presence of staining in follicular material would still contribute to detection and diagnosis of CWD-positive deer under field applications. Over 80% of the tonsillar lymphoid follicles showed some evidence of Pr<sup>Pres</sup> accumulation in >70% of the CWD cases diagnosed among harvested or culled mule deer (Fig. 2); this relatively uniform distribution should minimize false negative rates among biopsy samples. However, we recognize that a few deer may be sampled in a narrow time interval when the proportion of positive follicles is very low (<0.3). For these very early CWD cases, the probability of false-negative tests is higher than estimated by this correction factor.

Because CWD is relatively rare in infected free-ranging deer populations (Miller et al. 2000), few CWD-positive animals are encountered in sampling. Consequently, the likelihood of false-negative tests is already small. When CWD prevalence is estimated using tonsillar biopsy data, sample quality (measured by follicle count) and prevalence estimates can be used to correct the small probability of false negatives for a given sample (see Appendix 1). We used a beta distribution to approximate the distribution of the proportion

of positive follicles for our correction factor. A more thorough analysis would seek to estimate the parameter  $\pi(t)$  and the parameters of  $f(p)$  using a likelihood framework and model selection approach (Burnham and Anderson 1998). Although this approach probably would improve the correction function, for our data, the impact would be very slight because the probability of a false negative was small and because CWD prevalence, as estimated by either harvest or biopsy data, was relatively low (<0.16). We did not pursue a better fit because the correction factor for these data turned out to be trivial (<1.1% change in the estimates). In other situations, where data are collected in an area with higher prevalence and/or where more samples have very few follicles, this correction factor may be important. In such situations, pursuing a more appropriate function to model the proportion of positive follicles may be beneficial.

## MANAGEMENT IMPLICATIONS

The availability of a reliable test for diagnosing CWD in live mule deer offers several opportunities for advancing both understanding and management of this important wildlife disease. Antemortem testing may be the most viable alternative for conducting CWD surveillance in national parks and residential areas where deer are not harvested. Moreover, capturing and sampling deer in large numbers probably will be a more publicly acceptable initial means of assessing the infection status of populations residing in urban or rural residential areas in situations where CWD is rare or has not been previously documented. Antemortem testing provides a tool for intensively sampling local deer subpopulations to assess prevalence and identify foci of infection without unnecessarily disrupting established social structures or movement patterns. Our study demonstrates that prevalence data from captured deer can be used to augment data from harvested deer, thereby providing more seamless representation of spatial patterns of CWD distribution; such representations have particular utility in evaluating potential influences of land-use patterns on CWD epidemiology.

Early detection and removal of CWD-infected individuals appears to be the most effective method for managing CWD (Gross and Miller 2001). Selectively culling test-positive individuals should help reduce prevalence rates in endemic areas. Because Pr<sup>Pres</sup> accumulates in tonsillar follicles relatively early in the course of CWD infections

in mule deer (Sigurdson et al. 1999; E. S. Williams and M. W. Miller, unpublished data), culling biopsy-positive deer also should aid in reducing transmission rates in populations managed under test-and-slaughter regimes (Gross and Miller 2001). Such management strategies clearly warrant experimental evaluation under field conditions.

Despite its promising utility, we recognize the practical limitations of the CWD testing approach described here. The needs for capturing, anesthetizing, and precisely sampling individual deer limit the broad implementation of this testing approach in managing free-ranging deer populations infected with CWD. At best, this approach may find application in augmenting disease management programs based primarily on manipulating deer densities in endemic areas.

Antemortem testing does, however, offer more immediate application as a tool for screening captive deer to ensure that CWD-infected individuals are not being moved in commerce. Surveillance programs for CWD presently are lacking in the North American deer industry. Consequently, requiring CWD testing in mule deer or white-tailed deer prior to importation may be the most effective means for state and provincial wildlife managers to assure that CWD is not being imported or spread via commercial wildlife sales. (Based on our observations of CWD pathogenesis in white-tailed deer [E. S. Williams and M. W. Miller, unpublished data], tonsillar biopsy should be equally effective in detecting infections in this species.) If deer are being sampled to determine their individual infection status (e.g., for regulatory testing), then  $\geq 9$  follicles/sample would be needed to assure (with  $\geq 95\%$  confidence) that an individual deer was not infected with CWD (assuming that 0.3 is the minimum proportion of positive follicles present in a positive sample). Tonsillar biopsy, as described here, offers a relatively reliable live-animal test for CWD in deer. Whole-herd testing of commercial deer herds would be more likely to detect infected populations than testing individual animals, but either approach would be more effective than relying on subjective health certifications in assuring that privately owned deer are free from CWD infections prior to importation.

## ACKNOWLEDGMENTS

Deer were captured and handled in accordance with Colorado Division of Wildlife and Colorado State University Animal Care and Use Committee (ACUC) protocols (Colorado Division of Wildlife

ACUC 12-1999 and 07-2001, and Colorado State University ACUC 99-320A-01). We thank H. Hsieh, C. Krumm, K. Larsen, S. Liss, and R. Opsahl for assistance in the field, P. Jaeger for performing tonsillar IHC, and T. Terrell, Rocky Mountain National Park, and numerous property owners for facilitating access in our 2 study areas. Dr. B. Schreuder provided helpful advice on tonsil sampling techniques. Dr. W. Lance and Wildlife Pharmaceuticals, Inc. (Fort Collins, Colorado, USA), provided both drugs and technical advice instrumental in deer captures. D. Freddy and T. Sanders provided helpful comments on earlier manuscript drafts. Our study was funded by the Colorado Division of Wildlife, Federal Aid in Wildlife Restoration Project W-153-R, and National Science Foundation/National Institutes of Health Grant DEB-0091961.

## LITERATURE CITED

- ANDRÉOLETTI, O., P. BERTHON, D. MARC, P. SARRADIN, J. GROSCLAUDE, L. VAN KEULEN, F. SCHELCHER, J.-M. ELSÉN, AND F. LANTIER. 2000. Early accumulation of PrP<sup>Sc</sup> in gut-associated lymphoid and nervous tissue of susceptible sheep from a Romanov flock with natural scrapie. *Journal of General Virology* 81:3115–3126.
- BROWN, L. D., T. T. CAI, AND A. DASGUPTA. 2001. Interval estimation for a binomial proportion. *Statistical Science* 16:101–133.
- BURNHAM, K. P., AND D. R. ANDERSON. 1998. Model selection and inference: a practical information-theoretic approach. Springer-Verlag, New York, USA.
- CLOVER, M. R. 1956. Single-gate deer trap. *California Fish and Game* 42:199–201.
- COLORADO DIVISION OF WILDLIFE. 2001. Colorado Wildlife Commission policy: CWD final policy. <http://wildlife.state.co.us/hunt/HunterEducation/CWDfinalpolicy.asp> [Accessed 19 November 2001.]
- CONNER, M. M., C. W. MCCARTY, AND M. W. MILLER. 2000. Detection of bias in harvest-based estimates of chronic wasting disease prevalence in mule deer. *Journal of Wildlife Diseases* 36:691–699.
- GROSS, J. E., AND M. W. MILLER. 2001. Chronic wasting disease in mule deer: disease dynamics and control. *Journal of Wildlife Management* 65:205–215.
- MILLER, J. M., A. L. JENNY, W. D. TAYLOR, R. F. MARSH, R. RUBENSTEIN, AND R. E. RACE. 1993. Immunohistochemical detection of prion protein in sheep with scrapie. *Journal of Veterinary Diagnostic Investigation* 5:309–316.
- MILLER, M. W., AND E. S. WILLIAMS. 2002. Detecting PrP<sup>CWD</sup> in mule deer by immunohistochemistry of lymphoid tissues. *Veterinary Record* 151:in press.
- , C. W. MCCARTY, T. R. SPRAKER, T. J. KREEGER, C. T. LARSEN, AND E. T. THORNE. 2000. Epidemiology of chronic wasting disease in free-ranging cervids in Colorado and Wyoming. *Journal of Wildlife Diseases* 36:676–690.
- O'ROURKE, K. I., T. V. BASZLER, T. E. BESSER, J. M. MILLER, R. C. CUTLIP, G. A. H. WELLS, S. J. RYDER, S. M. PARISH, A. N. HAMIR, N. E. COCKETT, A. JENNY, AND



- D. P. KNOWLES. 2000. Preclinical diagnosis of scrapie by immunohistochemistry of third eyelid lymphoid tissue. *Journal of Clinical Microbiology* 38:3254–3259.
- , J. M. MILLER, T. R. SPRAKER, I. SADLER-RIGGLEMAN, AND D. P. KNOWLES. 1998a. Monoclonal antibody F89/160.1.5 defines a conserved epitope on the ruminant prion protein. *Journal of Clinical Microbiology* 36:1750–1755.
- , S. M. PARISH, AND D. P. KNOWLES. 1998b. Preclinical detection of PrP<sup>Sc</sup> in nictitating membrane lymphoid tissue of sheep. *Veterinary Record* 142:489–491.
- SCHREUDER, B. E. C., L. M. J. VAN KEULEN, M. E. W. VROMANS, J. P. M. LANGEVELD, AND M. A. SMITS. 1996. Preclinical test for prion diseases. *Nature* 381:563.
- , ———, ———, ———, AND ———. 1998. Tonsillar biopsy and PrP<sup>Sc</sup> detection in the preclinical diagnosis of scrapie. *Veterinary Record* 142:564–568.
- SIGURDSON, C. J., E. S. WILLIAMS, M. W. MILLER, T. R. SPRAKER, K. I. O'ROURKE, AND E. A. HOOVER. 1999. Oral transmission and early lymphoid tropism of chronic wasting disease PrP<sup>Pres</sup> in mule deer fawns. *Journal of General Virology* 80:2757–2764.
- SPRAKER, T. R., K. I. O'ROURKE, A. BALACHANDRAN, R. R. ZINK, B. A. CUMMINGS, M. W. MILLER, AND B. E. POWERS. 2002. Validation of monoclonal antibody F99/97.6.1 for immunohistochemical staining of brain and tonsil in mule deer (*Odocoileus hemionus*) with chronic wasting disease. *Journal of Veterinary Diagnostic Investigation* 14:3–7.
- VAN KEULEN, L. M. J., B. E. C. SCHREUDER, R. H. MELOEN, G. MOOIJ-HARKES, M. E. W. VROMANS, AND J. P. M. LANGEVELD. 1996. Immunohistochemical detection of prion protein in lymphoid tissues of sheep with natural scrapie. *Journal of Clinical Microbiology* 34:1228–1231.
- WILLIAMS, E. S., AND S. YOUNG. 1980. Chronic wasting disease of captive mule deer: a spongiform encephalopathy. *Journal of Wildlife Diseases* 16:89–98.
- , AND ———. 1982. Spongiform encephalopathy of Rocky Mountain elk. *Journal of Wildlife Diseases* 18:463–471.

Received 17 January 2002.

Accepted 29 March 2002.

Associate Editor: Peterson.

## APPENDIX 1

This appendix presents a correction factor for sample quality based on the probability that a deer was actually CWD-positive given that  $n$  negative follicles were present in the tonsil biopsy (i.e., a false-negative test result). The probability of a false-negative result can be defined as

$$p\{CWD\ positive | n\ negative\ follicles\} = \frac{(1-p)^n \pi}{(1-p)^n \pi + (1-\pi)}$$

where, for the biopsy sample representing 1 deer, all  $n$  sampled follicles were negative,  $p$  was the (unknown) proportion of all its tonsil follicles that were infected at the time ( $t$ ) the sample was taken, and  $\pi$  was the estimated tonsillar CWD prevalence rate in the population when the sample was taken (i.e., prevalence estimated at time  $t$  if every tonsil follicle was examined for all deer in the population). Using this probability, the expected correction factor ( $C_n$ ) for false-negative samples due to a small number of follicles present in a negative sample was

$$C_n = \int_0^1 \frac{(1-p)^n \pi}{(1-p)^n \pi + (1-\pi)} f_t(p) dp.$$

At this point, we needed to determine the probability distribution of  $p$  (fixed  $t$ , variable  $\Delta$ ) over the sampling population. Variation in  $p(\cdot)$  mainly is attributable to variation in  $\Delta$  (that is unknown). Conceptually,  $p(t)$  has some *pdf*, so let  $f(\cdot) = f(p) = f(p(t, \Delta))$ . Note, however, that the ran-

dom variable ( $p$ ) becomes a probability over each deer that would, in fact, be CWD-positive as identified by tonsillar IHC.

We calculated 2 estimates of  $\pi$ , 1 using harvest data collected in close spatial and temporal proximity to biopsy study areas (designed to sample the same population) and a second using tonsil biopsy data. To approximate  $f(p)$ , we used IHC slides from 64 harvested deer previously identified as CWD-positive (Miller and Williams 2002) to count the number of positive and negative follicles in representative cross-sections of tonsillar tissue. Only intact follicles were counted. From these count data, we constructed a frequency distribution for the relative proportions of positive follicles encountered in CWD-infected deer (Fig. 2). We used these data to assess what  $f(p)$  might be most appropriate for calculating the correction factor for false-negatives dependent on the number of follicles present in each biopsy sample collected.

We did not know  $f(p)$ . However, from our data,  $p$  appeared skewed toward 1 (Fig. 2), suggesting that if tonsil tissue tested positive, then generally it was strongly positive. The distribution of  $p$  (Fig. 2), supports the assumption that when 1 follicle was positive other follicles also became positive rapidly, so that in a very short time (perhaps weeks)  $p$  becomes large ( $>0.5$ ). This currently is our best approximation of  $f(p)$ . There appears to be little dependence of  $\pi(t)$  on time (Conner et al. 2000), and consequently we also assumed that  $f(p)$  was

relatively independent of time (i.e.,  $p(t)$  and  $f(p)$  may change over time, but only slowly). Using these assumptions and the frequency distribution of  $p$ , we approximated  $f(p)$  with a beta distribution,  $\text{beta}(3,1)$ , that yielded a probability density function of  $f(p) = 3p^2$ . Substituting this function into  $C_n$ ,

$$C_n = \int_0^1 \frac{(1-p)^n \pi}{(1-p)^n \pi + (1-p)} 3p^2 dp$$

provided an expression that we numerically integrated to calculate  $C_n$  for a given  $n$  and  $\pi$ . Note that for  $\pi$  in the vicinity of our data (Table 1), the correction factor is approximately 0, except when

$n$  is small ( $<5$ ). From this the corrected prevalence,  $\pi$ , was estimated as

$$\hat{\pi} = \frac{k_{\text{positive}} + \sum_{n=0}^{\infty} C_n(k_{\text{negative}}(n))}{k},$$

where  $k$  was the number of deer sampled and  $n$  was the number of negative follicles present in a biopsy sample. Assumptions underlying this correction factor included (1) the number of tonsil follicles collected in a biopsy was small compared to the total number of tonsil follicles available, (2) positive follicles were randomly distributed throughout the tonsil, and (3) false-positive results did not occur.